

# Prevention of inadvertent intra-operative trauma to alveolar antral artery utilizing Cone Beam Computed Tomography analysis

Zainab Akbar, Asif Ullah Qureshi, Faisal Ahsan, Nayab Iqbal, Sobia Salam, Kashmala Amirzada

## Submitted

August 10, 2022

## Accepted

October 15, 2022

## Author Information

*Dr Zainab Akbar*

Assistant Professor & Head  
Oral Medicine, Rehman  
College of Dentistry,  
Peshawar, Khyber  
Pakhtunkhwa, Pakistan  
(Corresponding Author)  
Email:

zainabakbar06@gmail.com

*Dr Asif Ullah Qureshi*

Assistant Professor  
Oral Medicine, Rehman  
College of Dentistry,  
Peshawar, Khyber  
Pakhtunkhwa, Pakistan

*Dr Faisal Ahsan*

Postgraduate Trainee in  
Prosthodontics, Sardar Begum  
Dental College, Peshawar,  
Khyber Pakhtunkhwa,  
Pakistan

*Dr Nayab Iqbal*

Demonstrator  
Oral Medicine, Rehman  
College of Dentistry,  
Peshawar, Khyber  
Pakhtunkhwa, Pakistan

*Dr Sobia Salam*

Assistant Professor  
Oral Biology, Rehman  
College of Dentistry,  
Peshawar, Khyber  
Pakhtunkhwa, Pakistan

*Dr Kashmala Amirzada*

Demonstrator  
Sardar Begum Dental  
College, Peshawar, Khyber  
Pakhtunkhwa, Pakistan

**Citation:** Akbar Z, Qureshi AU, Faisal, Iqbal N, Salam S, Amirzada K. Prevention of inadvertent intra-operative trauma to alveolar antral artery utilizing Cone Beam Computed Tomography analysis. J Rehman Med Inst. 2022 Oct-Dec;8(4):7-10.

## ABSTRACT

**Introduction:** Inadvertent injury to the alveolar antral artery during any surgical procedure involving the maxillary sinus can cause profuse bleeding. Literature reveals that there is a significant discrepancy in the course of this artery across various populations. During pre-surgical planning, Cone Beam Computed Tomography (CBCT) is utilized to prevent any unintended injury to the antral artery during implant placement.

**Objective:** To disclose the path of the alveolar antral artery utilizing CBCT in patients presenting to a tertiary care dental hospital of Peshawar, Khyber Pakhtunkhwa.

**Materials & Methods:** A cross sectional descriptive study was conducted from April 01, 2021, to March 30, 2022, on retrospective data of 608 CBCT maxillary scans of dentate patients who presented to Rehman College of Dentistry, Peshawar, during the year 2020. All CBCT images were acquired using CS 9000 (Care stream Dental, Atlanta, GA) with power requirements of 220V/20A and a 3D field of view of 5\*3.75 cm. The average distance of the alveolar antral artery from all four maxillary teeth in the posterior region was calculated. Data were analysed for descriptive statistics through statistical software SPSS 22.

**Results:** Out of 608 posterior maxillary areas examined the antral artery was detected in 442 (72.9%) areas. The average distance of antral artery from the posterior teeth in first and second quadrant was calculated to be 19.58 ± 5.69 mm.

**Conclusion:** Cone beam computed tomogram, in a presurgical planning phase, emerged as an essential and inevitable tool for analysing the presence and course of alveolar antral artery and its variations to minimise injury to the artery and its associated complications.

**Keywords:** Maxillary Sinus; Alveolar Antral Artery; Sinus Lift Surgery; Maxillary Implant; Cone Beam Computerized Tomography.

*The authors declared no conflict of interest. All authors contributed substantially to the planning of research, data collection, data analysis, and write-up of the article, and agreed to be accountable for all aspects of the work.*

## INTRODUCTION

Sinus lift surgery by lateral window approach is a harmless surgical approach for acquisition of bony matter for the placement of a dental implant,<sup>1</sup> however intra- and post-operative complications can occur. Haemorrhage by inadvertent trauma to the Alveolar Antral Artery (AAA), entrenched in the lateral wall of maxillary sinuses, can pose a challenge.<sup>2,3</sup> AAA provides supply to the wall of sinus, Schneiderian membrane, periosteum and posterior teeth.<sup>2,4,5</sup>

This locality of the artery can cause it to be damaged 20% of the time while performing any surgical procedure in this area.<sup>6</sup> Regardless of splitting the antral artery, it is not fatal. However, damaging this vessel can make the procedure complex since it can cause excessive bleeding, thus, blotting out the view of the surgical site, and might as well cause severing of the Schneiderian membrane, resulting in prolonging the entire procedure.<sup>7,8</sup> If the diameter of the artery is more than 0.5mm (1-2mm) in a patient, there is about 57% probability of a high risk of bleeding.<sup>9-11</sup>

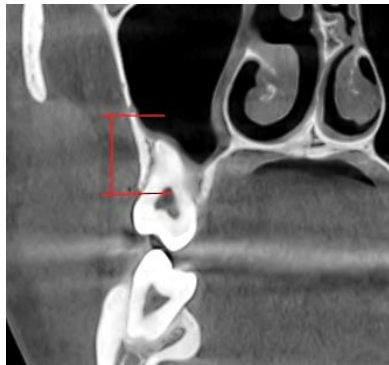
Formerly either CT scan, casts, and other radiographs have been used for planning but with variable success. Recent literature<sup>12-14</sup> has strongly endorsed employing cone beam computed tomography (CBCT) when planning surgery in order to carefully evaluate any anomaly in the anatomy of the sinus such as distance reduction between crest of the alveolar bone and alveolar antral artery, a bizarrely broad alveolar antral artery, or one with a complete intraosseous path, in an attempt to curtail bleeding complications. With respect to literature review, there is substantial disparity in the presence and course of the AAA across countries as well.<sup>15-20</sup>

Despite the importance of such studies and the common use of CBCT for presurgical planning, no research has been done in Pakistan till now, and the current study is the first to be published on this topic.

The present study was conducted to document and gauge the occurrence and locality of anterior antral artery in four of the maxillary posterior region teeth employing cone beam computed tomography in patients presenting to a tertiary care dental hospital of Khyber Pakhtunkhwa.

**MATERIALS & METHODS**

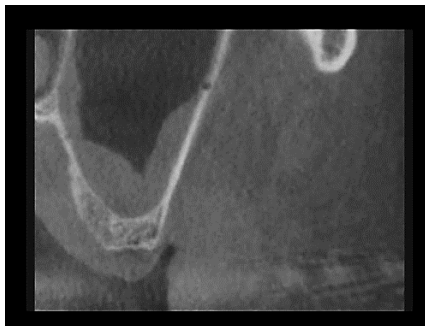A cross sectional descriptive study was conducted at Rehman College of Dentistry (RCD), Peshawar, Khyber Pakhtunkhwa, from April 01, 2021, to March 30, 2022, on retrospectively obtained CBCT data of the maxillary sinuses of 212 patients who underwent various dental procedures within the year 2020. A total of 608 maxillary sinus scans were scrutinised in this research. Permission was taken from the RCD Ethical Committee. The selection criteria included good quality CBCT images of dentate patients, showing bilateral maxillary sinuses and scans. The exclusion criteria included any pathologies, artefacts, previous surgeries, edentulous ridges, and first premolars appearing frontwards to the maxillary sinus. All CBCT images were acquired using CS 9000 (Carestream Dental, Atlanta, GA) with power requirements of 220V/20A and 3D field of view of 5\*3.75. Voxel size of 0.07 mm was employed in the image's reconstruction. All reconstructions and measurements were achieved with the employment of Care Stream imaging suite. For analysing the images, appropriate lighting in the



**Figure 1: Coronal view**

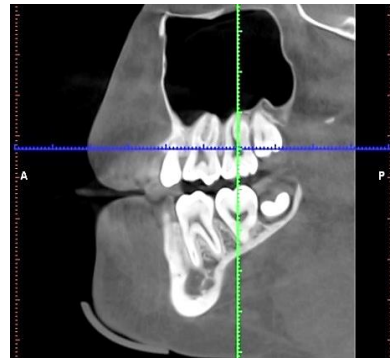Multiple views were evaluated to confirm the presence and location of the artery to avoid any artefacts. The distance was measured using ruler tool in the CBCT software. According to Guncu et al,<sup>13</sup> if there was an artery canal present, the length from the lower border of artery canal to the lowermost point of the buccal alveolar ridges at the centre of tooth areas was measured vertically if there was an artery canal present.

The parameters noted included A) Presence of the AAA canal visible on the reconstructed CBCT images; B) The location of the antral artery with regards to the ridge crest. When the canal was apparent on the CBCT images, the distance from the lowermost point of the buccal alveolar ridge to the most inferior part of the radiolucent canal was evaluated vertically and noted.



**Figure 3: Sagittal view**

background and a screen of computer (Intel® Core (TM) i3-3120M CPU @ 2.50GHz, Samsung Electronics Co. Ltd, Korea) were employed. As a pilot study, the CBCT images of randomly chosen 50 maxillary sinuses underwent evaluation twice with a gap of at least one month by each reviewer, supervised by an expert radiologist and an oral and maxillofacial surgeon. The intra-examiner variance was measured; Pearson correlation test of intra-examiner variance was calculated to be 0.987. The longitudinal and cross-sectional images assessed the occurrence and location of the antral alveolar artery. The artery was located according to the criteria mentioned by Apostolakis and Bissoon.<sup>16</sup> According to these authors, the occurrence of the artery canal should be investigated in the posterior region of last four maxillary teeth. In case of presence of antral artery, the distance was measured from artery's lower border to the buccal alveolar ridge crest at midpoint of both premolars, and the first two molars mesiodistally in coronal view (Figure 1). Sagittal view was used to confirm that measurements were taken at the midpoint of the tooth mesiodistally. (Figure 2).

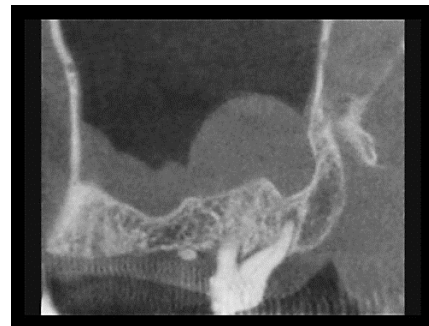

**Figure 2: Sagittal view**

Data were analysed employing the statistical software SPSS 22.0 (IBM, NY, USA). ANOVA was employed to test the differences of means of the distance of the artery from the crest of the alveolar bone of maxillary four teeth in the posterior areas. The mean distance of the canal of artery from alveolar crest of four teeth areas by gender were calculated via independent t test. A  $p \leq 0.05$  denoted significance.

**RESULTS**

Out of the total 608 posterior maxillary sinuses examined, the antral artery was detected in 442 (72.9%) CBCT images (Figures 3 & 4).



**Figure 4: Coronal view**

In the area of four maxillary teeth, the mean distance of the alveolar crest from the antral area are given in Table 1. The average distance of antral artery from the posterior teeth was  $19.58 \pm 5.69$  mm.

**Table 1: Means of distances between alveolar crest and antral artery compared by ANOVA (n=442).**

Tooth Area	(Mean $\pm$ SD) mm
1 <sup>st</sup> Premolar	26.3 $\pm$ 5.5
2 <sup>nd</sup> Premolar	22.1 $\pm$ 4.9
1 <sup>st</sup> Molar	16.4 $\pm$ 3.2
2 <sup>nd</sup> Molar	16.6 $\pm$ 3.6
p<0.001	

Comparison of the mean values for individual tooth between male and female revealed that the difference was statistically significant for 1<sup>st</sup> molar (Male= $17.1 \pm 2.8$ , female= $15.4 \pm 3.7$  p=0.006) and 2<sup>nd</sup> molar (Male= $17.3 \pm 3.9$ , Female= $15.6 \pm 3.2$  p=0.009) although the difference between the average of the 4 teeth for male ( $19.95 \pm 5.66$ ) and female ( $19.05 \pm 5.7$ ) was statistically insignificant (p=0.109 Independent T test).

**Table 2: Distance between alveolar crest and alveolar antral artery amongst male and female patients by Independent Sample T test (n=442).**

Tooth Area	Male	Female	p value
	(Mean $\pm$ SD) mm		
1 <sup>st</sup> Premolar	26.1 $\pm$ 6.5	26.8 $\pm$ 3.0	0.559
2 <sup>nd</sup> premolar	21.6 $\pm$ 5.1	22.4 $\pm$ 4.5	0.401
1 <sup>st</sup> Molar	17.1 $\pm$ 2.8	15.4 $\pm$ 3.7	0.006
2 <sup>nd</sup> Molar	17.3 $\pm$ 3.9	15.6 $\pm$ 3.2	0.009
Mean distance (mm)	19.95 $\pm$ 5.66	19.05 $\pm$ 5.7	0.109

## DISCUSSION

Dental Implants have surpassed all other modalities for teeth replacement, but presurgical planning on casts and radiographs is mandatory to ensure precise placements. Cone Beam Computed Tomography is a specialized radiography, which is used as a gold standard in presurgical implant planning. Various anatomic landmarks and structures can be identified beforehand. The antral artery was found in 72.9% of the patients in our research. In a prevalence meta-analysis research carried out by Centelles,<sup>4</sup> artery detection rate is 78.1% (95% CI=61.2-94.9%) by CBCT, similar to our study.

By contrast, CT-based studies have shown different detection rates. In the CT-based study by Rosano et al, it was detectable in 47% of the cases only.<sup>15</sup> In another CT-based research the vessel was detected in 60.3% of the CT scans.<sup>22</sup>

Basically, this variation in detection rate of AAA is due to the fact that CBCT is more reliable in measurements than CT scans. Secondly, CT scan has been shown to be incapable of unveiling small arteries that are less than 0.5mm and those with an intrasinus or complete extraosseous path.<sup>6,10</sup>

Iatrogenic trauma to this artery can happen during surgical procedures like open sinus lift that involves lateral maxillary sinus wall, Le Fort I fracture treatment, horizontal osteotomy of the maxilla, and Caldwell-Luc surgery.<sup>17</sup>

Former studies have shown that 15 mm distance from the alveolar crest is considered secure to avoid vascular mutilation.<sup>9, 11,13,14,18,19</sup> However, AAA is located in a close approximation to the ridge in a variable percentage of maxillary sinuses.<sup>20</sup> In cases where the distance from the AAA to the alveolar crest is diminished or the alveolar ridges are extremely atrophic<sup>9,11,12,21</sup> the risk for intra surgical bleeding from larger vessels (>2mm) is significantly increased.<sup>8,10</sup>

The extent to which the alveolar ridge has resorbed contributes towards this unpredictability in most cases. An average distance of the vascular bundle from the most apical point of alveolar ridge of 19 mm, and 16.4 mm, 16.9 mm in classes I, II and III respectively, has been reported by literature. However, the space between the antral artery and the alveolar crest is greatly decreased to 10.9 and 11.25 mm in conditions of severe atrophy (in classes IV, V and VI).

In the current research, the distance between anterior alveolar artery and alveolar crest in first premolar region was  $26.3 \pm 5.5$ , second premolar  $22.1 \pm 4.3$ , first molar  $16 \pm 3.2$  and second molar  $16.6 \pm 3.6$  mm. In a Korean population, average distance from premolar region is  $20.62 \pm 3.05$  and  $17.50 \pm 2.84$  mm in the molar region.<sup>20</sup> Contrastingly, in a study conducted by Mung et al<sup>22</sup> the canal of the artery was located  $24.62 \pm 3.5$ mm,  $20.35 \pm 4.74$ ,  $15.82 \pm 4.09$  and  $15.93 \pm 3.57$  from the alveolar crest at both the premolars, and first two molars. In a study done by Centelles,<sup>4</sup> with results similar to the current study, the mean distance of AAA from crest was 15.26 mm, but only first molar was used as a reference point. In a study conducted by Kim et al,<sup>11</sup> CT images, lengths from both premolar and first two molar areas were 18.90 mm and 15.45 mm respectively which matched our results. Hence, average distances of artery from various teeth are almost the same except for some minor differences. These differences can be attributed to inter-rater reliability and difference of software or CBCT used. Greatest strength of our study is that it is first of its kind in Pakistan and provides practical insight into a very important matter.

## LIMITATION

Since this was a single institute study, the findings cannot be generalized to the entire population of Khyber Pakhtunkhwa.

## CONCLUSION

Cone beam computed tomogram, in a presurgical planning phase, emerged as an essential and invaluable tool for analysing the presence and course of alveolar antral artery and its variations to minimise injury to the artery and its associated complications.

## RECOMMENDATION

More research work needs to be done in multiple centres in the country for investigating other anatomic landmarks related to maxillary sinus.

It is the need of the hour that dentists adopt CBCT as a gold standard for evaluating the presence and exact location of an important landmark like alveolar antral artery to prevent inadvertent injury to it and avoid consequent complications.

## REFERENCES

1. Chiapasco M, Casentini P, Zaniboni M. Bone augmentation procedures in implant dentistry. *Int J Oral Maxillofac Implants.* 2009;24 Suppl:237-59.
2. Zijderveld SA, van den Bergh JPA, Schulten EAJM, ten Bruggenkate CM. Anatomical and surgical findings and complications in 100 consecutive maxillary sinus floor elevation procedures. *J Oral Maxillofac Surg.* 2008 Jul;66(7):1426-38.
3. Ella B, Sédarat C, Noble RDC, Normand E, Lauerjat Y, Siberchicot F, et al. Vascular connections of the lateral wall of the sinus: surgical effect in sinus augmentation. *Int J Oral Maxillofac Implants.* 2019 Dec ;23(6):1047-52.
4. Varela-Centelles P, Loira-Gago M, Seoane-Romero JM, Takkouche B, Monteiro L, Seoane J. Detection of the posterior superior alveolar artery in the lateral sinus wall using computed tomography/cone beam computed tomography: A prevalence meta-analysis study and systematic review. *Int J Oral Maxillofac Surg.* 2015;40:1405-10.
5. Solar P, Geyerhofer U, Traxler H, Windisch A, Ulm C, Watzek G. Blood supply to the maxillary sinus relevant to sinus floor elevation procedures. *Clin Oral Implants Res.* 1999;10(1):34-44.
6. Elian N, Wallace S, Cho S-C, Jalbout ZN, Froum S. Distribution of the maxillary artery as it relates to sinus floor augmentation. *Int J Oral Maxillofac Implants.* 2019 Dec 19;20(5):784-7.
7. Chanavaz M. Sinus grafting related to implantology. Statistical analysis of 15 years of surgical experience (1979-1994). *J Oral Implantol.* 1996;22(2):119-30.
8. Maridati P, Stoffella E, Speroni S, Ciccio M, Maiorana C. Alveolar antral artery isolation during sinus lift procedure with the double window technique. *Open Dent J.* 2014 Jun 16;8(1):95-103.
9. Rodella LF, Labanca M, Boninsegna R, Favero G, Tschabitscher M, Rezzani R. Intraosseous anastomosis in the maxillary sinus. *Minerva Stomatol.* 2010;59(6):349-54.
10. Rahpeyma A, Khajehahmadi S, Amini P. Alveolar antral artery: Does its diameter correlate with maxillary lateral wall thickness in dentate patients? *Iran J Otorhinolaryngol.* 2014;26(76):163-7.
11. Kim JH, Ryu JS, Kim KD, Hwang SH, Moon HS. A radiographic study of the posterior superior alveolar artery. *Implant Dent.* 2011 Aug;20(4):306-10.
12. Ilgüy D, Ilgüy M, Dolekoglu S, Fisekcioglu E. Evaluation of the posterior superior alveolar artery and the maxillary sinus with CBCT. *Braz Oral Res.* 2013;27(5):431-7.
13. Güncü GN, Yildirim YD, Wang HL, Tözüm TF. Location of posterior superior alveolar artery and evaluation of maxillary sinus anatomy with computerized tomography: A clinical study. *Clin Oral Implants Res.* 2011 Oct;22(10):1164-7.
14. Aung CM, Panmekiat S, Pimkhaokham A. The study of the alveolar antral artery canal in a group of Thai population using cone beam computed tomography. *Mahidol Dent J.* 2017;37:63-9.
15. Rosano G, Taschieri S, Gaudy JF, Weinstein T, Del Fabbro M. Maxillary sinus vascular anatomy and its relation to sinus lift surgery. *Clin Oral Implants Res.* 2011 Jul;22(7):711-5.
16. Apostolakis D, Bissoon AK. Radiographic evaluation of the superior alveolar canal: measurements of its diameter and of its position in relation to the maxillary sinus floor: a cone beam computerized tomography study. *Clin Oral Implants Res.* 2014 May;25(5):553-9. doi: 10.1111/clr.12119. Epub 2013 Feb 18.
17. Rahpeyma A, Khajehahmadi S. Alveolar antral artery: Review of surgical techniques involving this anatomic structure. *Iran J Otorhinolaryngol.* 2014;26(75):73-8.
18. Bernardi S, Mummolo S, Ciavarelli LM, Li Vigni M, Continenza MA, Marzo G. Cone beam computed tomography investigation of the antral artery anastomosis in a population of Central Italy. *Folia Morphol.* 2016 Jun 6;75(2):149-53.
19. Kang SJ, Shin S II, Herr Y, Kwon YH, Kim GT, Chung JH. Anatomical structures in the maxillary sinus related to lateral sinus elevation: A cone beam computed tomographic analysis. *Clin Oral Implants Res.* 2013 Aug;24(A100):75-81.
20. Park W-H, Choi S-Y, Kim C-S. Study on the position of the posterior superior alveolar artery in relation to the performance of the maxillary sinus bone graft procedure in a Korean population. *J Korean Assoc Oral Maxillofac Surg.* 2012;38:71-7.
21. Valente NA. Anatomical considerations on the alveolar antral artery as related to the sinus augmentation surgical procedure. *Clin Implant Dent Relat Res.* 2016;18:1042-50.
22. Mung C, Aung S, Panmekiat S, Pimkhaokham A. The study of the alveolar antral artery canal in using cone beam computed tomography. *Dent J.* 2017;37(1):63-9.