

# Endometriosis in an appendectomy scar: a case report

Jamil Ahmad, Muhammad Haseeb, Fayeza Javaid, Shahid Hasnain Siddiqui

**Submitted**

December 11, 2022

**Accepted**

December 22, 2022

**Author Information**

From: Department of Surgery,  
Rehman Medical Institute,  
Peshawar, Khyber  
Pakhtunkhwa, Pakistan

*Dr. Jamil Ahmad*

Professor & HoD

*Dr. Muhammad Haseeb*

House Officer

(Corresponding Author)

Email:

muhammadhaseeb0314@gmail.com

*Dr. Fayeza Javaid*

Junior Registrar

*Dr. Shahid Hasnain Siddiqui*

Postgraduate Trainee

Department of Pathology

**Citation:** Ahmad J, Haseeb M, Javaid F, Siddiqui SH. Endometriosis in an appendectomy scar: a case report. [Case Report]. J Rehman Med Inst. 2022 Oct-Dec;8(4):21-3.

**ABSTRACT**

Endometriosis is an abnormal growth of functional endometrial glands outside the endometrium causing pain and/or infertility, commonly found in females of childbearing age. The most common locations for endometriosis are the ovaries, pelvic cavity, and peritoneum. Other important locations for endometriosis include scars from previously operated surgical sites, for example cesarean section scars and cholecystectomy scars. Endometriosis found in an appendectomy scar is one of the rarest sites for endometriosis and only a few cases have been reported in the literature. The correct diagnosis of an appendectomy scar endometriosis is the base for an efficient treatment. Complete surgical excision is the preferred treatment for such cases. Herein we are reporting a case of endometriosis in an appendectomy scar.

**Keywords:** Endometriosis; Appendectomy; Scar; Endometriosis.

*The authors declared no conflict of interest. All authors contributed substantially to the planning of research, data collection, data analysis, and write-up of the case report, and agreed to be accountable for all aspects of the work.*

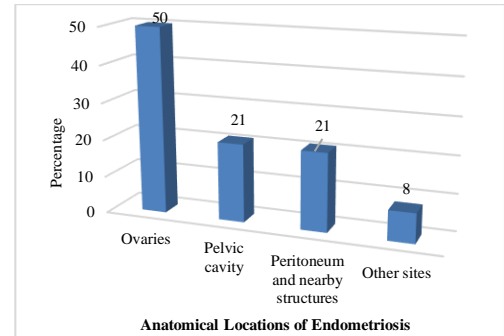
**INTRODUCTION**

Endometriosis is a non-neoplastic growth of endometrium-like glands or stroma at a location outside the endometrium.<sup>1</sup> The most common locations of endometriosis include the ovaries, pelvic cavity, peritoneum, and less commonly, the pouch of Douglas.<sup>2</sup>

Endometriosis has also been reported in surgical scars of patients who underwent various abdominopelvic surgeries for example cesarean section, hysterectomy, cholecystectomy, and rarely after appendectomy.<sup>3-7</sup>

Of all the locations, endometriosis in an appendectomy scar is rarely reported in the literature, and only a few cases are found in the whole literature.<sup>3</sup> In this case report, we describe a female patient who developed endometriosis in an appendectomy scar and how she was managed successfully in our hospital.

The graph given below represents the relative location-wise occurrence of endometriosis in patients<sup>2</sup> (Figure 1).



**Figure 1: Relative occurrence of endometriosis at various locations**

**CASE PRESENTATION**

A 35-year-old lady presented to our hospital on 5th September 2022. The chief complaints of the patient were cyclic pain and swelling on a previous appendectomy scar. The patient was operated on for acute appendicitis, and an appendectomy was done in 1995 (27 years back when she was 8 years old). The postoperative period was uncomplicated and the patient recovered successfully after being operated on.

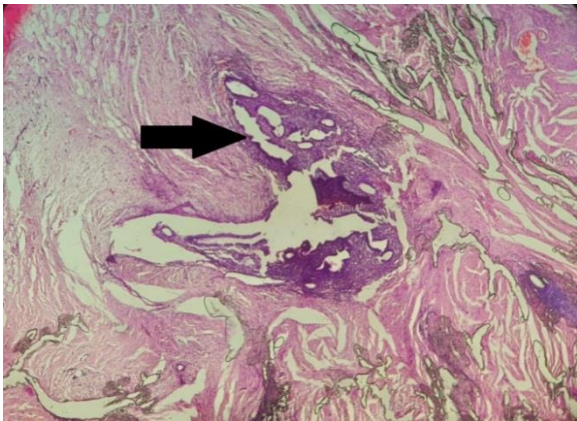
At the time of presentation, the patient was otherwise normal on general physical examination. On inspection of the abdomen, there was a swelling in the appendectomy scar of the patient. The patient also had a cesarean section scar on the abdomen. The patient's past surgical history was also significant for three cesarean sections all of which had a normal post-operative period.

The abdomen was soft, nontender, and non-distended. The bowel sounds were normal. The rest of the abdominal examination was normal. The chest was clear bilaterally and there were no crypts or wheezes. The patient had normal vesicular breathing. There were no murmurs on cardiovascular examination and both S1 and S2 heart sounds were normal.

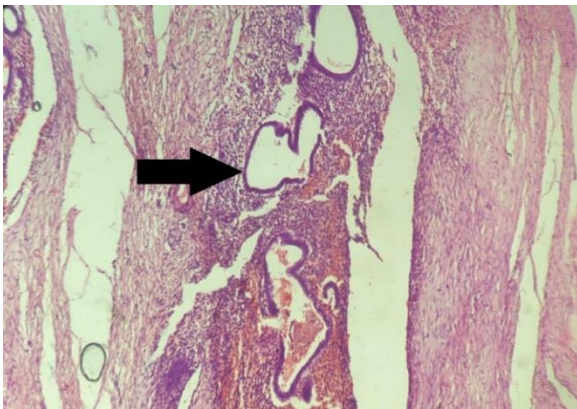
All laboratory values including complete blood count, renal function tests, and random blood sugar were normal. The patient was also negative for HbsAg, Anti HCV antibodies, and Anti-HIV antibodies. The patient's Covid 19 PCR was also negative.

## HISTOPATHOLOGY

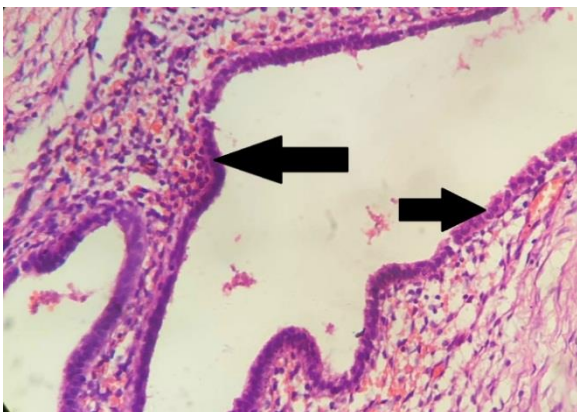
A biopsy sample was taken from the scar tissue. Figures 2, 3 & 4 all represents the histopathology slides of the scar tissue.



**Fig 2: Endometrial glands at 4X lens power.**



**Fig 3: Endometrial glands at 10X lens power.**



**Fig 4: Individual cells of the endometrial gland at 40X lens power.**

## DISCUSSION

Endometriosis is one of the most prevalent diseases in the female population.<sup>1,2</sup> It presents with cyclic pain that correlates with the menstrual cycle.<sup>3</sup> Cyclic pain is one of the hallmark features of endometriosis.<sup>1</sup> Patients with endometriosis often present with overlapping features with other diseases, making it difficult to diagnose and treat the condition.<sup>8</sup> Although the most common location of endometriosis includes the ovaries, pelvic cavity, and peritoneum, it sometimes presents on unusual sites for example in an appendectomy scar tissue. Surgical scar endometriosis has been reported in literature widely, but endometriosis in an appendectomy scar is an extremely rare condition and not commonly found in literature.<sup>3-7</sup> All such unusual sites of endometriosis should be reported to be added to the bank of literature.

The most widely accepted treatment for any surgical scar endometriosis is complete surgical excision of the affected area.<sup>8</sup> In the case of our patient biopsy of the swelling in the appendectomy scar was done. The biopsy report showed endometriosis in scar tissue. Complete surgical excision of the affected area was planned and surgery was performed. All of the abnormal tissue was excised and skin was sutured end to end. The surgery went uneventfully. The post-operative period was normal without any complications. After being operated the patient reported no cyclic pain as before. The patient is followed postoperatively and has remained symptom-free after being operated on. This makes surgical excision of scar endometriosis as treatment of choice. Therefore it is recommended that, after appropriate biopsy proven diagnosis of endometriosis in scar tissue is made, complete surgical excision should be considered as primary treatment modality. All the discussion in this case is about management of an appendectomy scar endometriosis only. The management of endometriosis, however, varies not only with location of the endometriosis but also with size of the abnormality. The involvement of nearby organs also change the management of the condition. Depending on the location of the condition the management varies widely from case to case.

## CONCLUSION

Endometriosis in an appendectomy scar is an extremely rare location for endometriosis. A female patient presenting with cyclic pain and swelling in previously operated scar tissue, scar endometriosis must be included in the differential diagnosis. A correct diagnosis of the condition is necessary for efficient treatment. Complete surgical excision of the abnormal tissue is recommended treatment and usually cures most cases.

## REFERENCES

1. WHO. Endometriosis. [Webpage]. World Health Organization. 2022. Available at: [https://www.who.int/news-room/fact-sheets/detail/endometriosis#:~:text=Endometriosis%20is%20a%20disease%20where,a%20girls%20globally%20\(2\).](https://www.who.int/news-room/fact-sheets/detail/endometriosis#:~:text=Endometriosis%20is%20a%20disease%20where,a%20girls%20globally%20(2).)
2. Mayo Foundation for Medical Education and Research. Endometriosis. Symptoms & Causes. [Webpage]. Mayo Clinic. 2018. Available at: <https://www.mayoclinic.org/diseases-conditions/endometriosis/symptoms-causes/syc-20354656>.
3. Amini M, Moghbeli M. Appendectomy scar endometriosis: a case report. *Mid East J Digest Dis.* 2018;10(2):114-6. <https://doi.org/10.15171%2Fmejdd.2018.100>.
4. Fatima K, Khanani S. Scar endometriosis: an entity not to be forgotten. *J Pak Med Assoc.* 2017;67(1):140-2.
5. Akbulut S, Sevinc, M, Bakir, S, Cakabay B, Sezgin A. Scar endometriosis in the abdominal wall: a predictable condition for experienced surgeons. *Acta Chir Belg.* 2010 May-Jun;110(3):303-7.

- <https://doi.org/10.1080/00015458.2010.11680621>
6. Emre A, Akbulut S. Laparoscopic trocar port site endometriosis: a case report and brief literature review. *Int Surg* 2012;97(2):135-9. <https://doi.org/10.9738/cc124.1>.
  7. Purbadi S, Purwoto G, Winrato H, Nuryanto KH, Scovani L, Sutarduga E. Case report: cesarean scar endometriosis, a rare entity. *Int J Surg Case Rep.* 2021 Aug;85:106204. <https://doi.org/10.1016/j.ijscr.2021.106204>.
  8. Mayo Foundation for Medical Education and Research. Endometriosis. Diagnosis & treatment. [Webpage]. Mayo Clinic. 2018. Available at: <https://www.mayoclinic.org/diseases-conditions/endometriosis/diagnosis-treatment/drc-20354661>.
-